

## **Introduction**

Damage to left perisylvian regions often results in phonological alexia/agraphia syndromes, which are characterized by disproportionate difficulty reading or spelling novel sequences of phonemes or graphemes (pseudowords) compared to real words. A relatively small literature has documented that a sequence of behavioral treatments directed toward phonological skills and phonology-orthography relations can improve reading and spelling performance on pseudowords, with additional functional benefits for written language skills overall (e.g. Beeson et al., 2010). However, the neural substrates supporting these improvements remain to be elucidated. Because phonological processing is a strongly left-lateralized skill in most literate adults, we hypothesized that neural support for improvement is likely to remain in the left hemisphere. To examine this hypothesis, we conducted pre and post treatment fMRI with an individual with acquired phonological alexia/agraphia due to left hemisphere stroke before and after administration of treatment sequence to improve phonological skills.

## **Methods**

### Case Summary

Mr. J. was a 51 year-old, right-handed male with 12 years of education who was evaluated one year post-stroke. He had a left MCA stroke which damaged dorsal perisylvian language areas, including supramarginal gyrus (SMG), posterior superior temporal gyrus (STG), and inferior frontal gyrus (IFG). Comprehensive language assessment revealed marked phonological impairment with relatively preserved lexical and semantic knowledge consistent with a profile of phonological agraphia/alexia. His performance on the Western Aphasia Battery (WAB) was consistent with Anomic aphasia with an Aphasia Quotient of 82.2. His score on the Boston Naming Test was 50/60. His disproportionately impaired phonological manipulation skills and impaired knowledge of phonology/orthography relations characterize a profile of phonological agraphia/alexia (Figure 1).

### Behavioral Intervention

A sequence of treatments were implemented during hour-long sessions conducted twice weekly with homework assigned daily. First, treatment was directed toward retraining phonology-orthography relations and improving phonological manipulation skills through blending of novel CVC pseudowords. Though it was challenging, Mr. J. ultimately achieved the criterion of 80% performance or better over two successive sessions on four sets of five consonants, two sets of six vowels, and four sets of five pseudowords. Mastery for both letter-to-sound and sound-to-letter relationships was achieved over the course of 20 weeks of treatment. The second focus of treatment involved applying those relearned phonological skills in conjunction with a computerized speller to assist with spelling during the construction of words, phrases, and sentences.

Following treatment, Mr. J. showed significant improvement on a battery of phonological tasks involving phoneme-grapheme conversion and sublexical phonological manipulation requiring verbal or nonverbal responses (Figure 2).

### Neuroimaging

To look at the regions involved in phonological tasks, Mr. J. was scanned using BOLD fMRI as he performed an overt pseudoword reading task (Figure 3). Eight control participants were also scanned to validate the task with respect to existing fMRI literature and to provide a basis of comparison to Mr. J's activation. Stimuli were presented in an event-related paradigm with an interstimulus interval jittered between 6-16 seconds to optimally deconvolve the hemodynamic response function (HDR). Mr. J was scanned on two occasions prior to beginning therapy, and on two occasions following each phase of intervention. Each session consisting of two runs of the experimental paradigm. Controls performed 2 consecutive runs of the paradigm during one session. Overt reading responses were recorded over an MRI compatible microphone for offline scoring. For Mr. J. pre-treatment and post-treatment signal changes were compared using a fixed effects model. Activation for controls was modeled in a random effects model following a fixed effects model for each subject. Activation maps were thresholded voxelwise at  $p < 0.005$ , then corrected for multiple comparisons based on cluster extent using GRFT ( $p < 0.05$ , corrected).

## **Results**

### Behavioral

On the pseudoword reading task in the scanner, normals performed at or near ceiling (mean of 90%). Consistent with the treatment outcome, Mr. J's average pseudoword reading accuracy in the scanner improved from 30% to 50.5% and then 55.8% following treatment (Figure 3).

### Neuroimaging of Controls

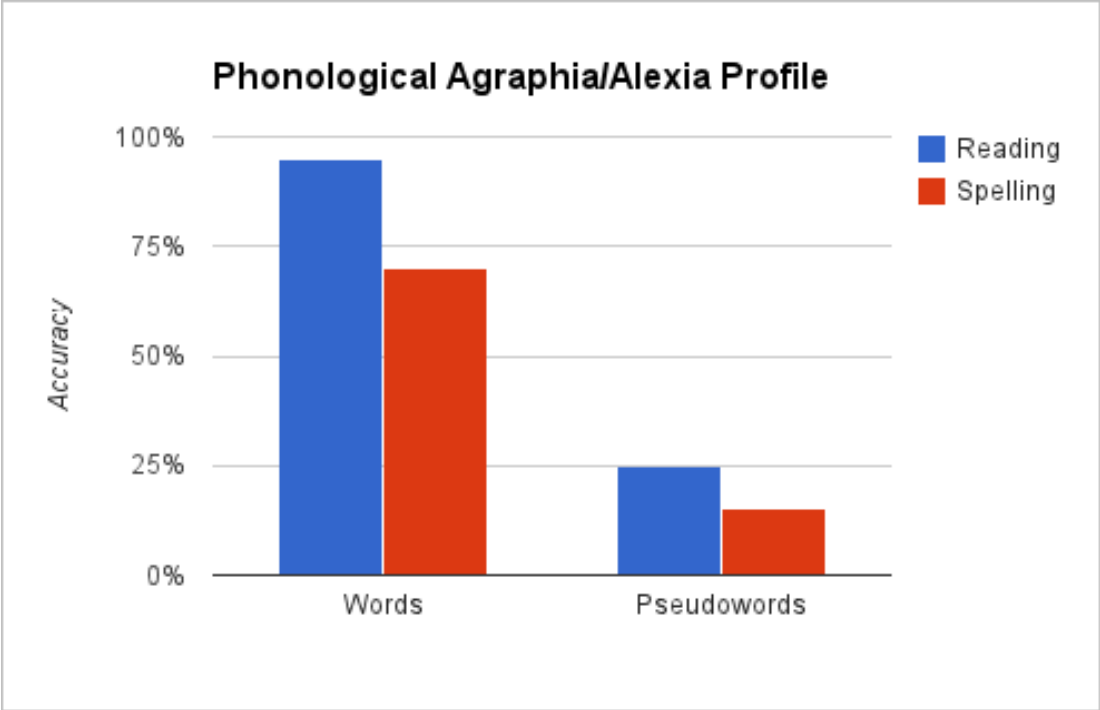
In the cohort of eight normal controls, a contrast of pseudoword reading versus rest revealed significant regions of activation including bilateral sensorimotor cortex, left inferior frontal gyrus (IFG), right middle temporal gyrus (MTG), and bilateral inferior occipito-temporal cortex.

### Neuroimaging of Mr. J

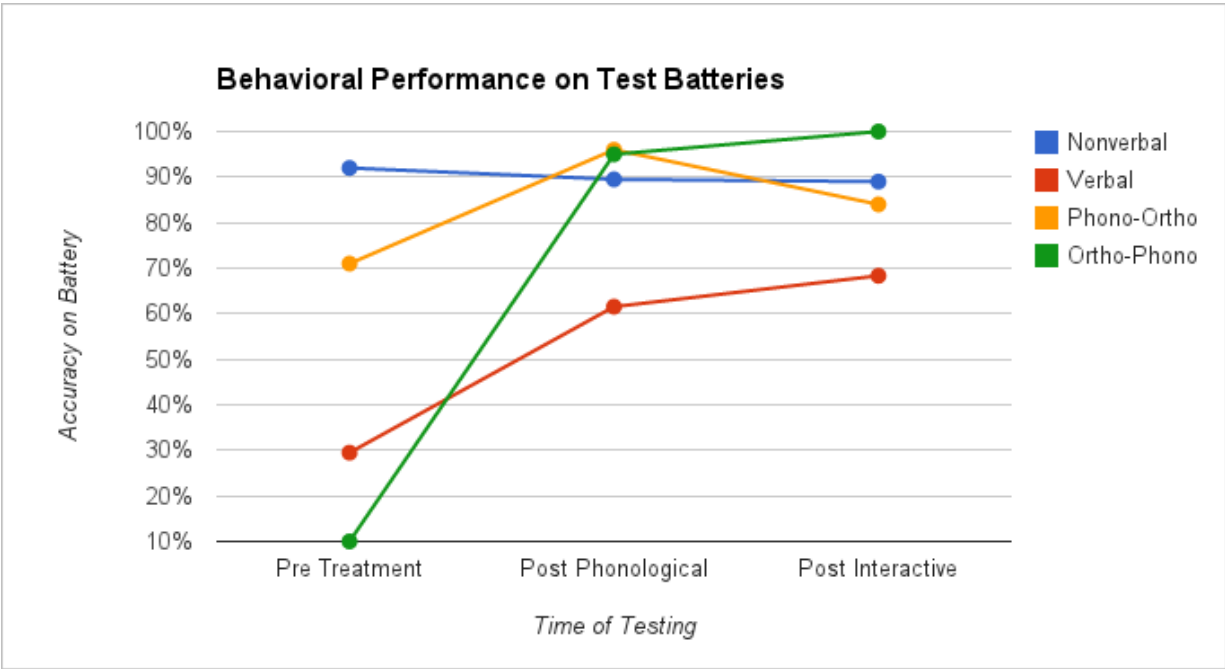
Both prior to and following treatment, significant regions of activation included bilateral sensorimotor cortex, left MTG, and bilateral inferior occipito-temporal cortex. Following treatment, increased activation was observed in left sensorimotor cortex, perilesional left inferior parietal lobule, and bilateral intra-parietal sulci (IPS). Decreased activation was observed in left posterior superior temporal sulcus/MTG and right IFG (Figure 4).

## **Discussion**

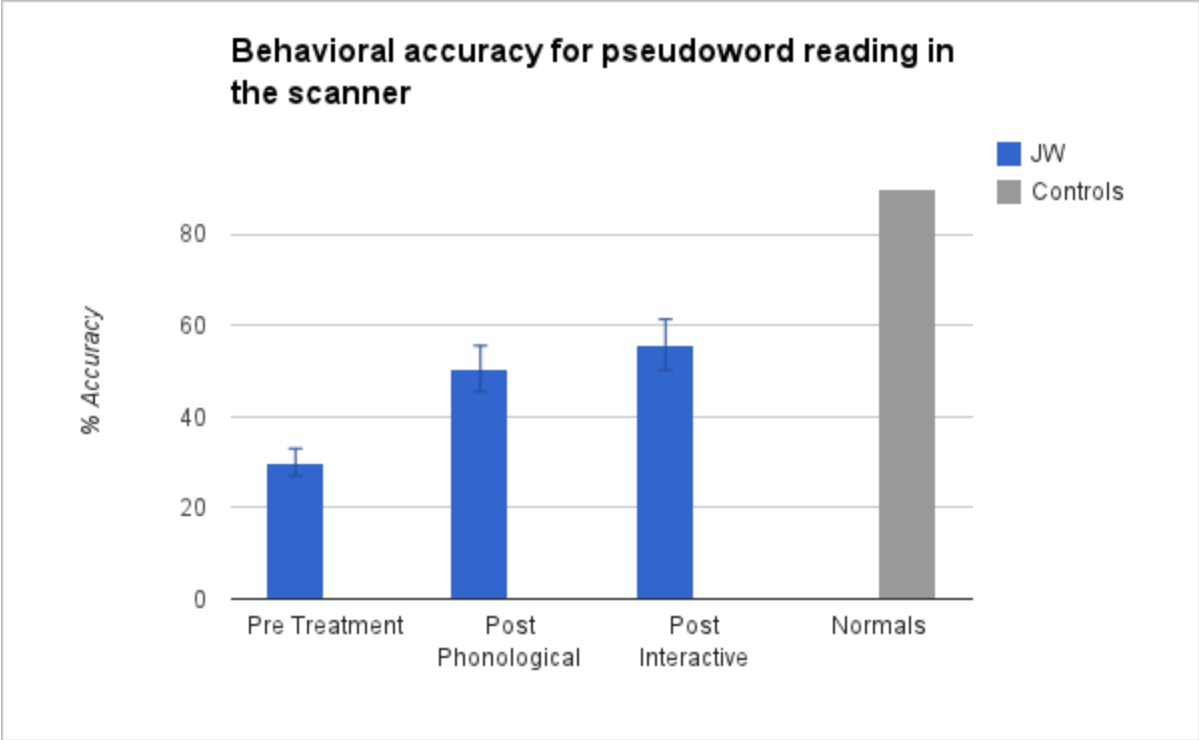
Mr. J showed marked improvement of phonological skills in response to the behavioral intervention, which generalized to improved behavioral performance in the scanner. The fMRI paradigm resulted in activation in normal controls that was similar to that previously reported in the literature, including left cerebellum, and left posterior inferior temporal gyrus, left inferior frontal and bilateral occipital cortices (e.g. Mechelli et al, 2003). Prior to treatment, Mr. J. activated regions similar to controls except that left hemisphere activation did not extend into ventral motor and pre-motor cortex, despite structural sparing, presumably due to dysfunctional tissue. Mr. J also activated left STG, suggesting reliance on lexical-semantic mechanisms for reading, as evidenced by his tendency to lexicalize pseudowords. Following treatment, Mr. J. appears to rely on the same cortical network with several notable changes including increased activation of bilateral IPS, left sensorimotor cortex, and a decrease in activation in left MTG. IPS has been hypothesized as supporting verbal working memory (Owen, 2005) and sublexical phonological processing in particular (Taylor et al., 2012). Increased activation in sensorimotor cortex may reflect the return to normal function of this region in the reading network. It was somewhat surprising that improved task performance was not associated with increased reliance on left inferior frontal gyrus, which was partially structurally spared. Decreased activation in left posterior MTG is consistent with reduced reliance on lexical-semantic processing subserved by the temporal lobe, reflecting an increased ability to read pseudowords in a phonological manner. These results are consistent with our hypothesis that improvements in phonological skills are supported by left hemisphere resources, and suggest that neuroimaging holds promise for characterizing the neural substrates and cognitive mechanisms of treatment-induced recovery of phonological processing skills.



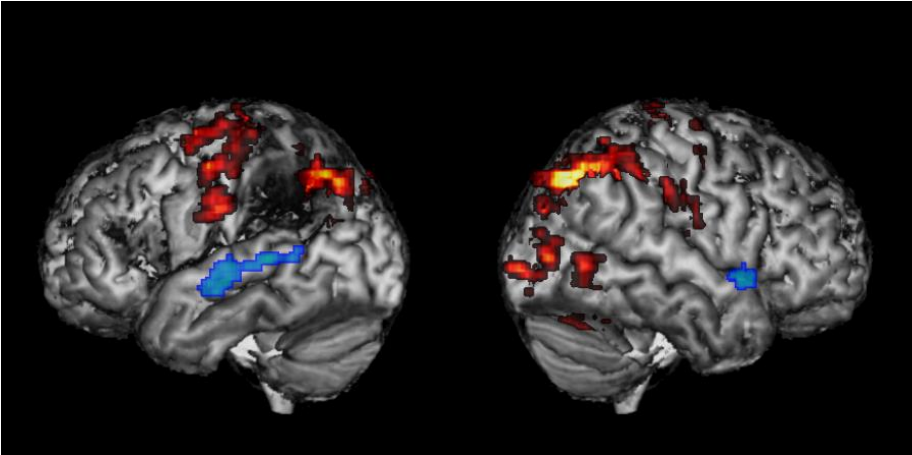
**Figure 1.** Mr. J’s behavioral profile reading and spelling words and pseudowords, consistent with phonological alexia/agraphia.



**Figure 2.** The effect of treatment on Mr. J’s performance on four phonological batteries relying on either nonverbal responses (blue), verbal responses (red), phonology to orthography conversion (yellow), or orthography to phonology conversion (green).



**Figure 3.** Mr. J's Accuracy for pseudoword reading before and after treatments (blue). Average performance of 8 controls shown for comparison (gray).



**Figure 4.** Percent signal change for Mr. J. following treatment, significant differences post>pre in hot, post<pre in cool (voxelwise  $p < 0.005$ ).

## Works Cited

- Beeson, P.M., Rising, K., Kim, E.S., & Rapcsak, S.Z. (2010). A treatment sequence for phonological alexia/agraphia. *J Speech Lang Hear Res.*, 53(2), 450-468.
- Mechelli, A., Gorno-Tempini, M.L., & Price, C.J. (2003). Neuroimaging studies of word and pseudoword reading: consistencies, inconsistencies, and limitations. *J Cognitive Neurosci*, 15(2), 260-271.
- Owen, A.M., McMillan, K.M., Laird, A.R., & Bullmore, E. (2005). N-back working memory paradigm: a meta-analysis of normative functional neuroimaging studies. *Hum Brain Mapp.*, 25(1), 46-59.
- Taylor, J.S.H., Rastle, K., & Davis, M.H. (2012). *Can cognitive models explain brain activation during word and pseudoword reading? A meta-analysis of 36 neuroimaging studies.* Psychol Bull.